

PERFORMANCE IN DIGITAL MAMMOGRAPHY WITH AND WITHOUT FILM PRIOR MAMMOGRAMS

Sián Taylor-Phillips

Applied Vision Research Centre,
Loughborough University, LE11 3UZ

Dr Alison Duncan

Warwickshire, Solihull and
Coventry Breast Screening
Service, University Hospital,
Coventry, CV2 2DX

Dr Matthew Wallis

Cambridge Breast Unit,
Addenbrookes Hospital,
Cambridge, CB2 2QQ

Prof. Alastair G. Gale

Applied Vision Research Centre,
Loughborough University, LE11 3UZ

Introduction: For the first 3 years after the introduction of digital mammography the prior mammograms (from the previous screening round) are in film format. There are difficulties making comparisons between digital current and film prior mammograms due to differences in image appearance and display brightness. Whilst the performance benefits of using prior mammograms are well documented, there is no evidence of whether film prior mammograms are still of use in digital mammography. This study investigates cancer detection performance in digital mammography with and without film prior mammograms.

Method: Two radiologists and two radiography advanced practitioners read a set of 160 (41% malignant) difficult digital mammography cases twice, once with film prior mammograms and once without. Participants rated probability of malignancy for each case and noted whether they would recall each case in the NHS breast screening programme.

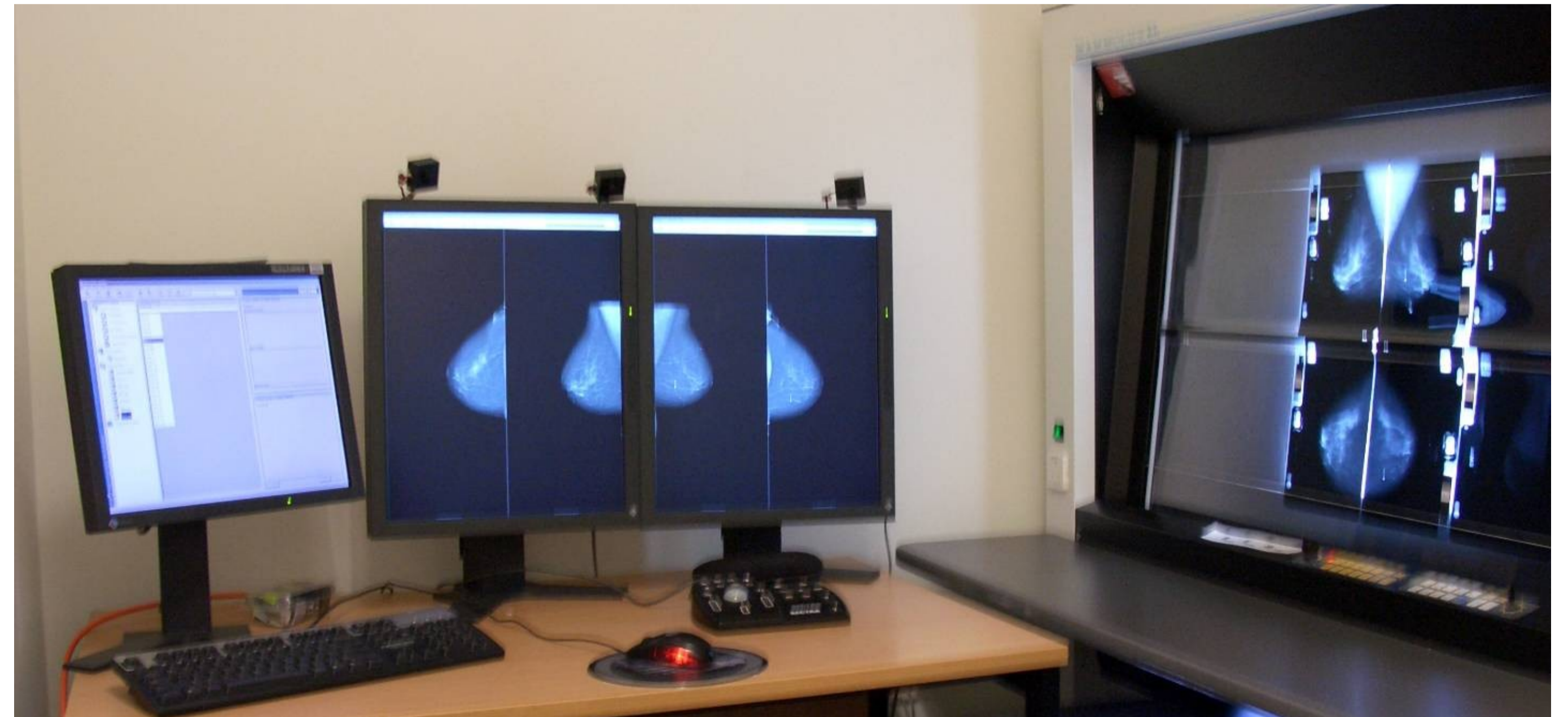


Figure 1. A digital mammography workstation with the film prior mammograms displayed

Results: There was a trend towards a larger number of false positive cases (i.e. normal cases which were recalled) when prior mammograms were not available, (24% increase, $p=.058$). This is illustrated in figures 2 and 3. If this trend continued throughout the NHS Breast Screening Programme then discarding prior mammograms would correspond to an increase in recall rate from 4.6% to 5.3%, and 12,414 extra women recalled annually for assessment. The number of false negative cases (i.e. missed cancers) did not differ between conditions.

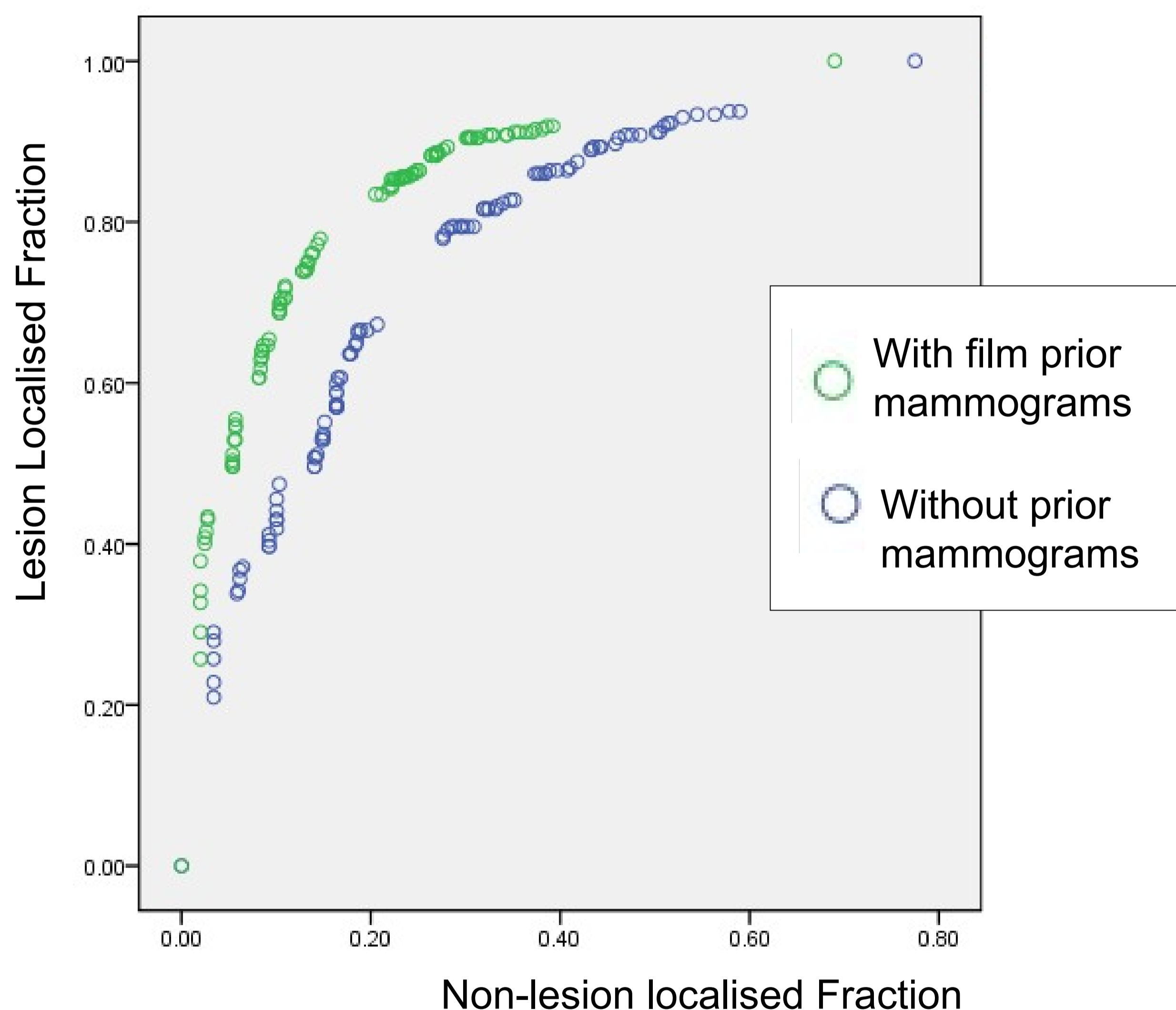


Figure 2. FROC curve of performance in digital mammography. A curve which is higher and further to the left indicates superior performance

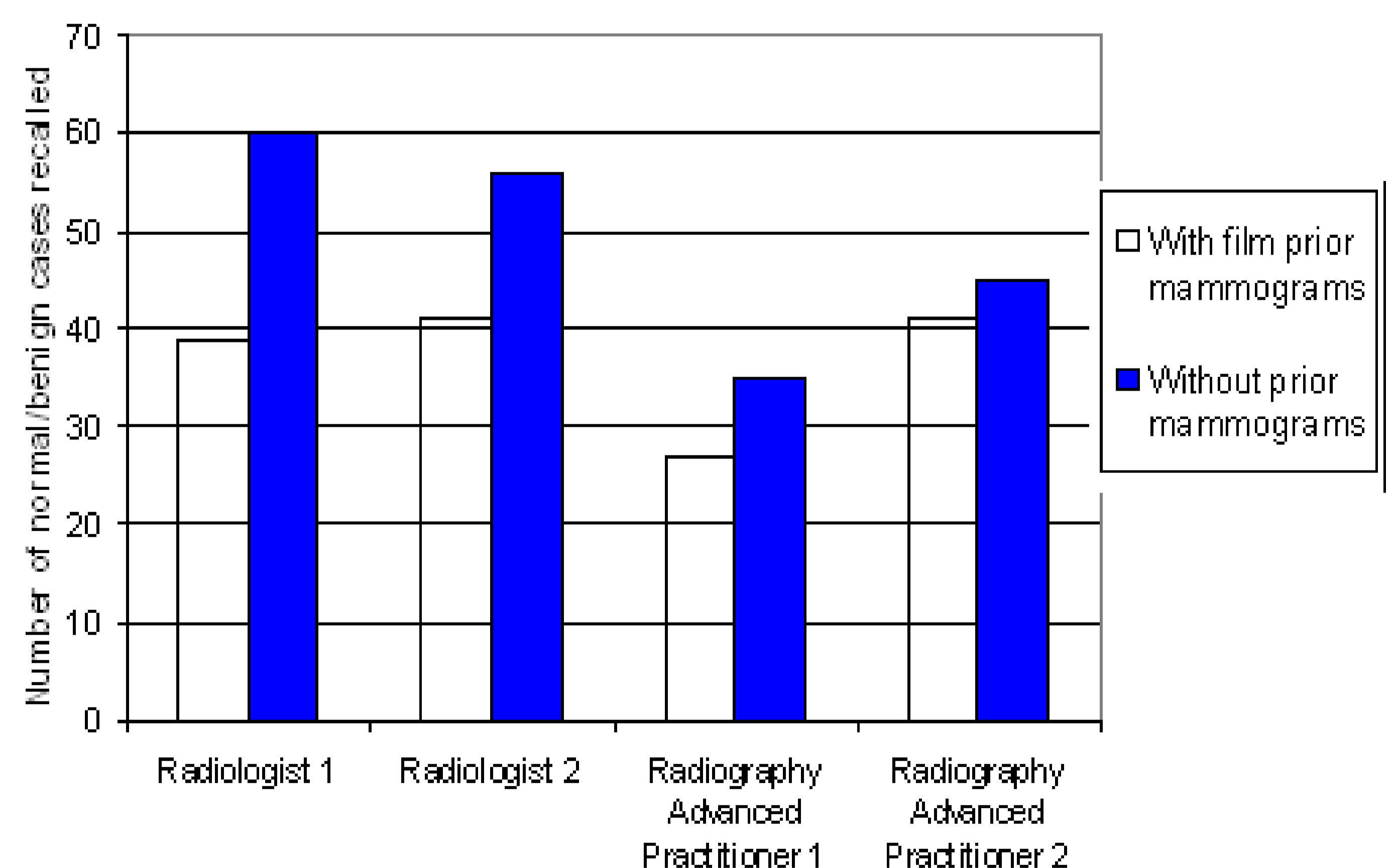


Figure 3. Number of difficult benign/normal cases recalled using digital mammography both with and without film prior mammograms

Conclusion: Initial results indicate that film prior mammograms may be beneficial to cancer detection performance in digital mammography, and therefore should be displayed. Further results are available from Sian Taylor-Phillips S.Taylor-Phillips@warwick.ac.uk