

# UNDERESTIMATION OF INVASIVE MALIGNANCY ON AUTOMATED CORE BIOPSY OF BREAST

Dr Bhavani Rengabashyam, Dr Jennifer Findlay and Mrs Judith Kelly  
Countess of Chester Hospital NHS Foundation Trust

## Introduction

- Accurate pre operative diagnosis is paramount in the management of the breast cancer patient. Recent recommendations suggest that non-operative diagnosis of impalpable invasive carcinoma should be achieved in at least 85% of breast cancer patients with a target of more than 90%. (1)
- The Chester breast screening unit routinely employs stereotactic 14g automated core device (ACD) in the interrogation of impalpable microcalcifications (MCL) with vacuum assisted biopsy (VAB) being reserved for difficult cases. Review of literature highlights that ACB underestimates invasive disease more often than VAB, (table 1). (2)

Table 1

Study	Biopsy device	Underestimation rate
Liberman et al., 2002	11g VAB	20% (12/60)
Bagnall et al., 2001	14g ACD	20.6% (14/68)
Darling et al., 2000	14g ACD	21% (14/67)
Won et al., 1999	11g VAB	10% (18/175)
Burbank, 1997	14g ACD	35% (7/20)
Liberman et al., 1995	14g ACD	16% (9/55)
Jackman et al., 1994	14g VAB	0% (0/32)
	14g ACD	20% (3/15)
	14g ACD	19% (8/43)

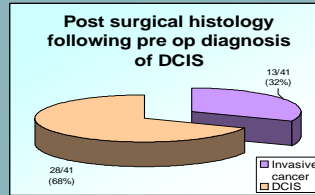
## Methods

- Retrospective review of all biopsy proven screen detected cases of DCIS from August 2004 to March 2009.
- All biopsies were performed with 14g cutting needle mounted on the Bard automated device and performed by experienced breast practitioners. Pre-operative biopsy results were compared with post operative histology.

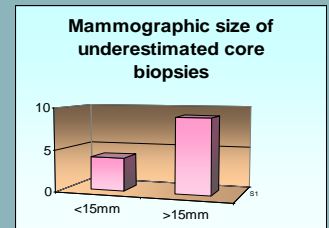
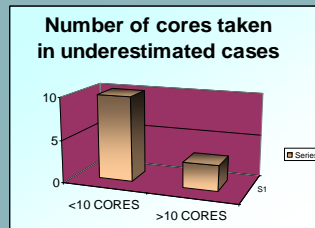
## Procedural Variables

Patient variable	Age Range Mean	52-82 65.3
Mammographic lesion variable	MCL Mass diameter (mm)	38 3
	<10 10-20 >20	10 13 18
Procedural variables	Specimens obtained per lesion Calc in specimen radiograph	Range 2-12 Mean 3.8 Median 5 38

## Results



Total number of screen detected DCIS cases = 41



## Discussion

Core biopsy is the standard preoperative tool in the management of breast cancer patients. Whilst it is sensitive in the detection of cancers, it substantially underestimates invasive malignancy. Table 1 highlights the published data in this respect. Inaccurate targeting is not a frequent cause for this since image guidance and specimen radiography are routinely employed. Limited sampling seems to be the main contributory factor. The degree of underestimation varies with gauge of needle, type of device, size of lesion, and number of cores obtained particularly for micro calcifications but not the type of lesion (ie) mass or micro calcifications. (2) Several studies have concluded that vacuum device consistently performs better than ACD in the detection of invasive malignancy. (2, 3) In our small series, we have found this pattern as well. However, the challenge of underestimation is not eliminated by using VAB alone. Consideration of certain imaging features can drive down the rate of underestimation. First of all, the size of lesion has a positive association with invasive malignancy, therefore, it has been suggested that more samples have to be obtained. Jackman et al suggested obtaining more than 10 specimens per cluster and removal of entire cluster if <10mm. As Bagnall et al suggested the more numerous the cluster, the higher the rate of invasive malignancy, therefore we should aim to sample a wider area.

## Conclusion

Our study is in line with the evidence in published literature that ACB underestimates invasive malignancy substantially more (15%-36%) when compared to VAB (0-20%) (2). It also reveals as does other studies that the greater the size of the cluster of calcification, the higher the rate of underestimation (3). It would be ideal to perform VAB to interrogate MCL, but until it becomes widely available on the NHS, we should aim to obtain at least 10 or more cores from the lesion whenever possible and sample a wider area for larger lesions in order to obtain a more representative specimen (3).

2. Underestimation of malignancy of breast core-needle biopsy: concepts and precise overall and category-specific estimates. Cancer 2007; Feb 109(3):487-95  
3. Stereotactic breast biopsy of Nonpalpable breast lesions: Determinants of Ductal Carcinoma in situ Underestimation Rates. Radiology 2001;Feb 218;497-502